

Homeopathic Laminated Flowcharts

Originally Seen in *Homeopathy Today*

Developed and Produced by

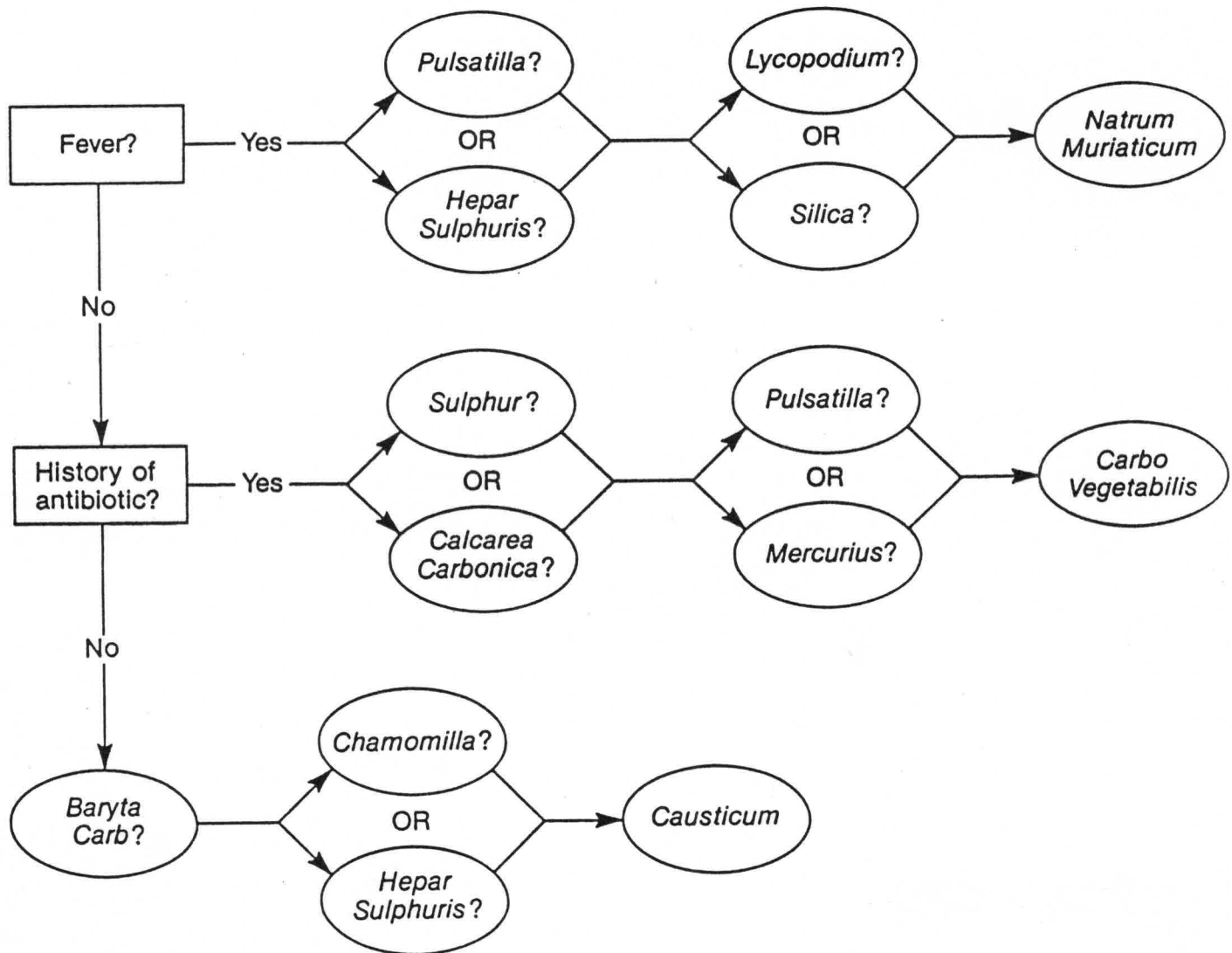
PRACTICAL PUBLICATIONS

Stephen Myles Davidson, D.O.
1303 West Bethany Home Road
Phoenix, Arizona 85013

In AZ 602-246-8977
In USA 800-359-7772

ACUTE OTITIS MEDIA

You diagnose acute otitis media in a child.



PLEASE NOTE: This information is to be used only under your doctor's supervision.

TRAUMATIC MAN

ARNICA... use first in all injury; for shock, pain, bleeding, etc.

Blows to Head, Spine or Coccyx:
HYPERICUM

Blackeye
LEDUM

Heatstroke:
BELLADONNA
GLONOINE
ANT. CRUD

Chillblains:
AGARICUS
CALC. CARB.

Nerve injury:
HYPERICUM

Wrist sprain
Wrist ganglion
RUTA

HYPERICUM

Fracture:
ARNICA & LEDUM
& SYMPHYTUM

Wounds, Cuts & Bleeding:
CLENDULA ☺
HYPERICUM ☺

Bruises:
LEDUM

Joint Sprains:
RHUS-TOX or **RUTA**

Muscular Strains:
ARNICA

Tendon injury:
RUTA

Old Sprains:
Poison Ivy:
RHUS - TOX

Insect or Animal bites:
LEDUM

BUZZZZZZ

Bee sting:
APIS

Burns:
CANTHARIS - internal
CALENDULA ☺ } externally
HYPERICUM ☺
URTICA URENS ☺

Puncture wounds:
LEDUM

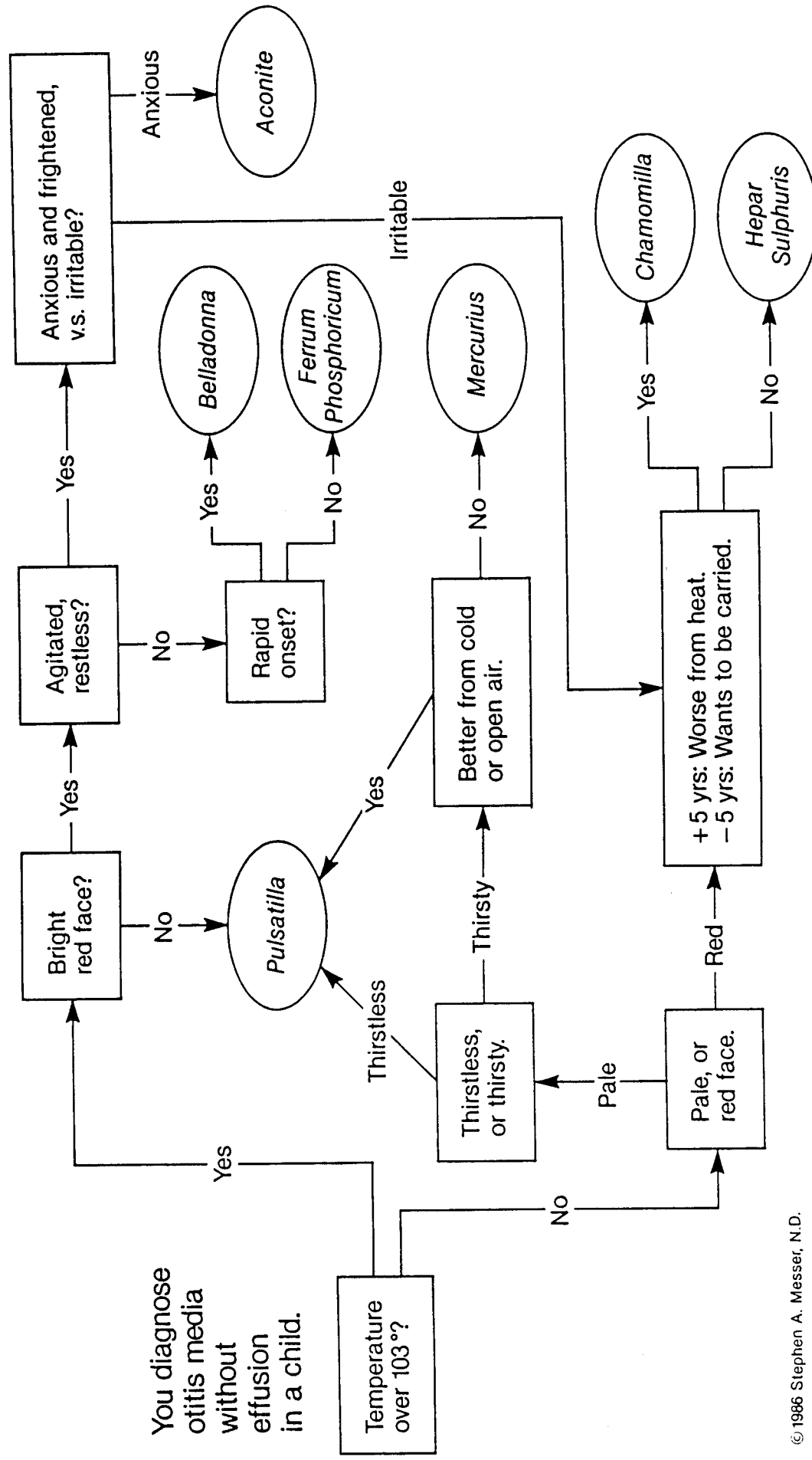
Splinters, etc.
SILICA
(to expell foreign body)

Abuse of Alcohol, Drugs, Smoking, Food: **NUX VOMICA**

Reprinted with permission by: PRACTICAL PUBLICATIONS, 1303 West Bethany Home Road, Phoenix, AZ 85013 (602) 246-8977

Please Note: This information is to be used only under your doctor's supervision.

OTITIS MEDIA WITHOUT EFFUSION



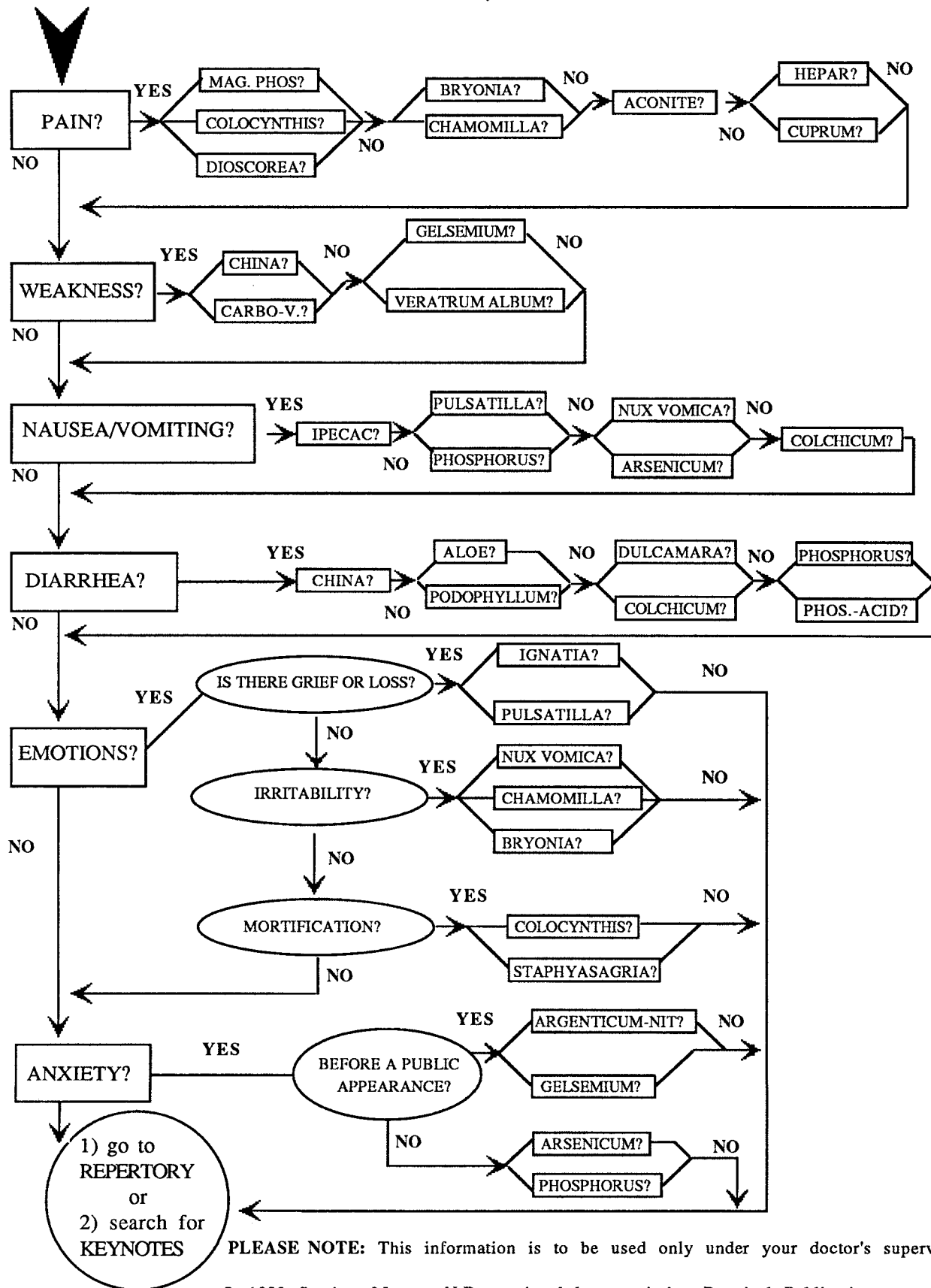
Please note : This information is to be used only under your doctor's supervision.

A CHART OF ACUTE GASTRO-INTESTINAL DISORDERS

by Stephen Messer, N.D.

Is the main problem:

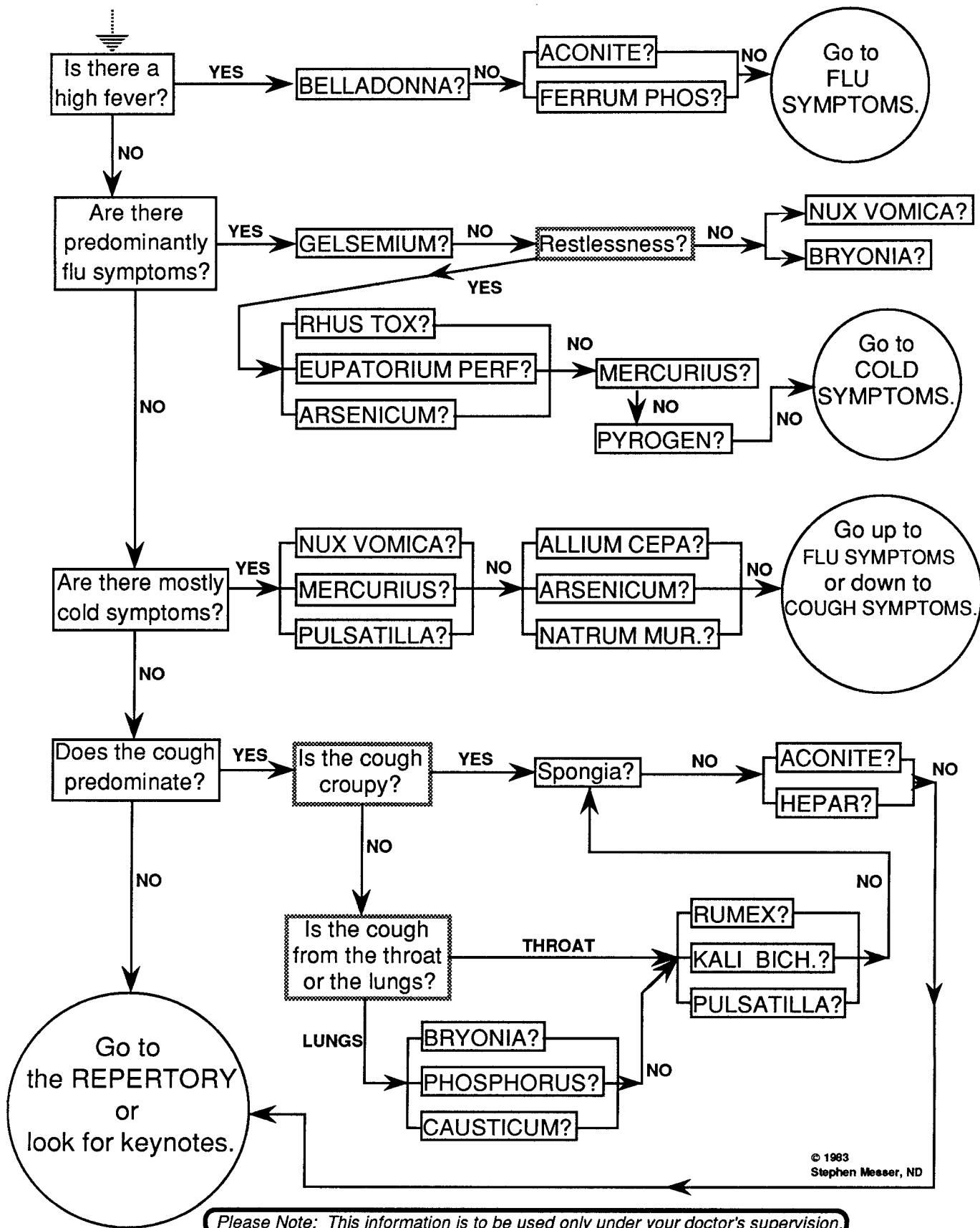
***NOTE:** acute pain in the abdomen is often a very serious problem. See your doctor first.



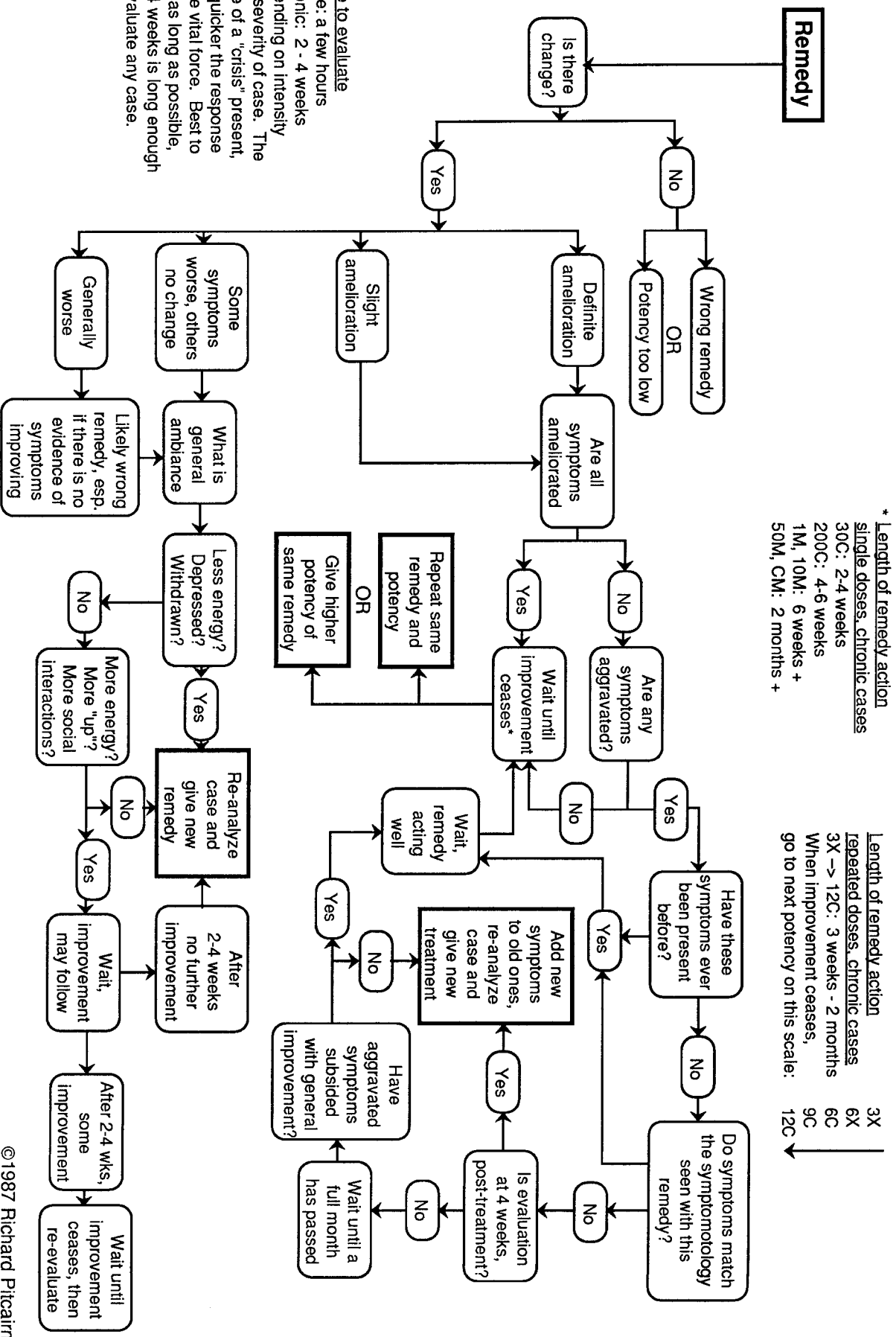
PLEASE NOTE: This information is to be used only under your doctor's supervision.

A CHART OF SIMPLE COLDS, FLUS, AND COUGHS

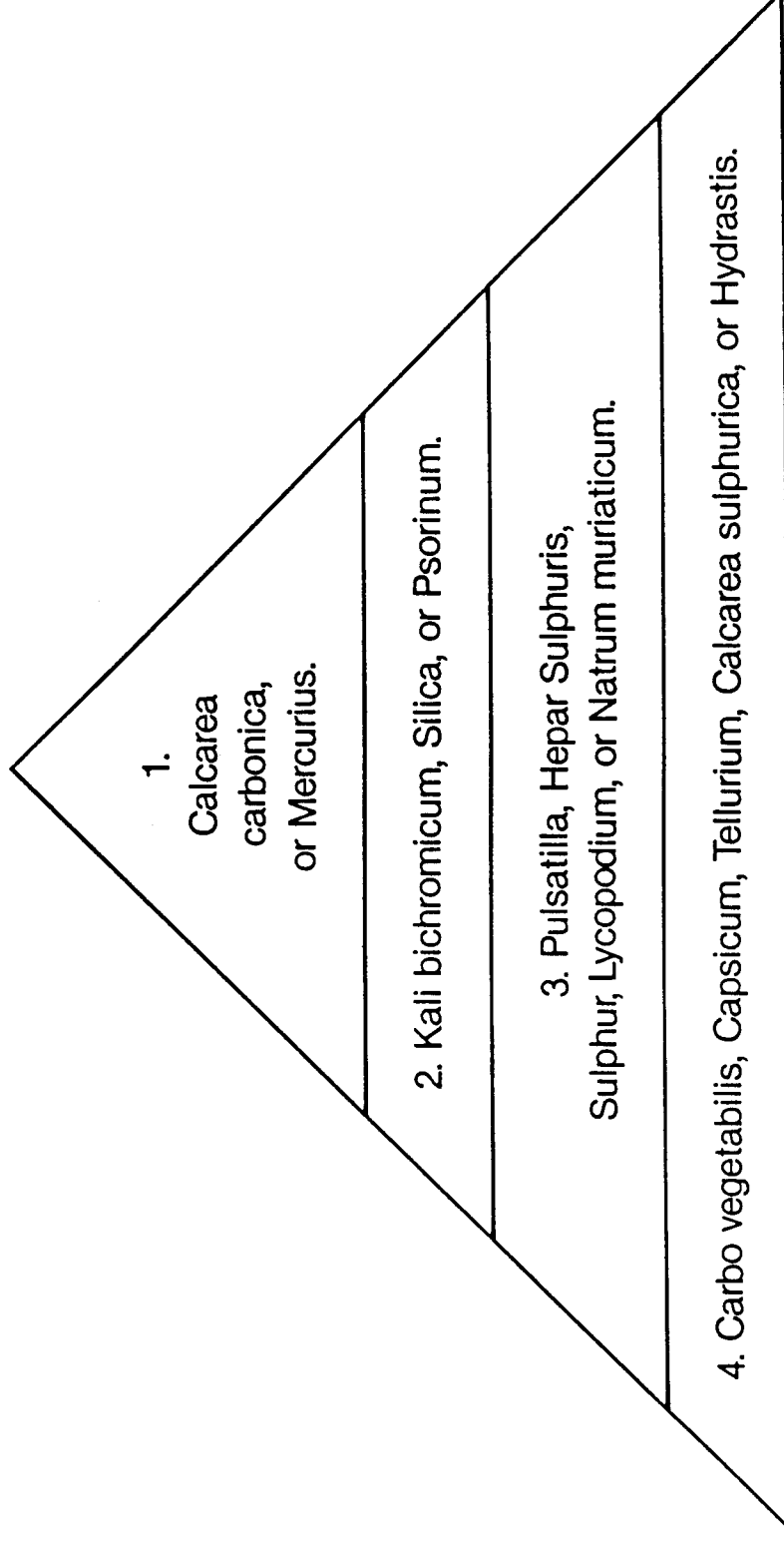
by Stephen Messer, ND



TIMING OF HOMEOPATHIC REMEDIES



CHRONIC OTITIS MEDIA

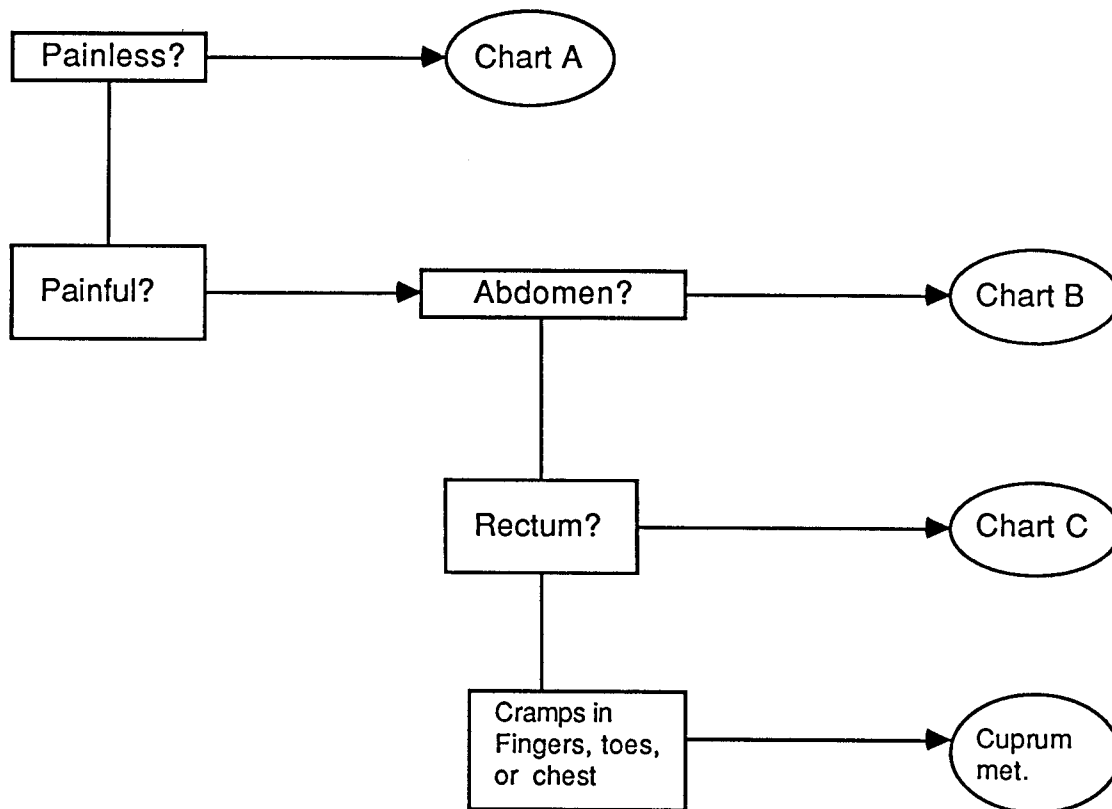


©1986 Stephen A. Messer, N.D.

Please note : This information is to be used only under your doctor's supervision.

ACUTE GASTROENTERITIS FLOW CHARTS

Use the most characteristic situation to direct you to the correct chart.

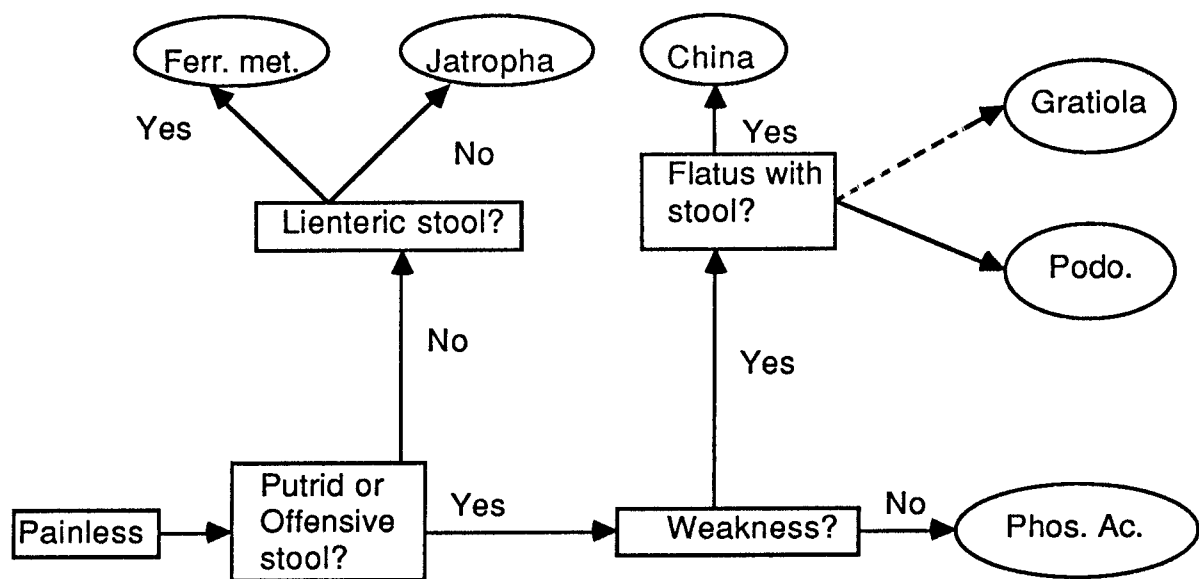


Please note : This information is to be used only under your doctors supervision.

© STEPHEN A. MESSER, ND APRIL, 1987

CHART "A"

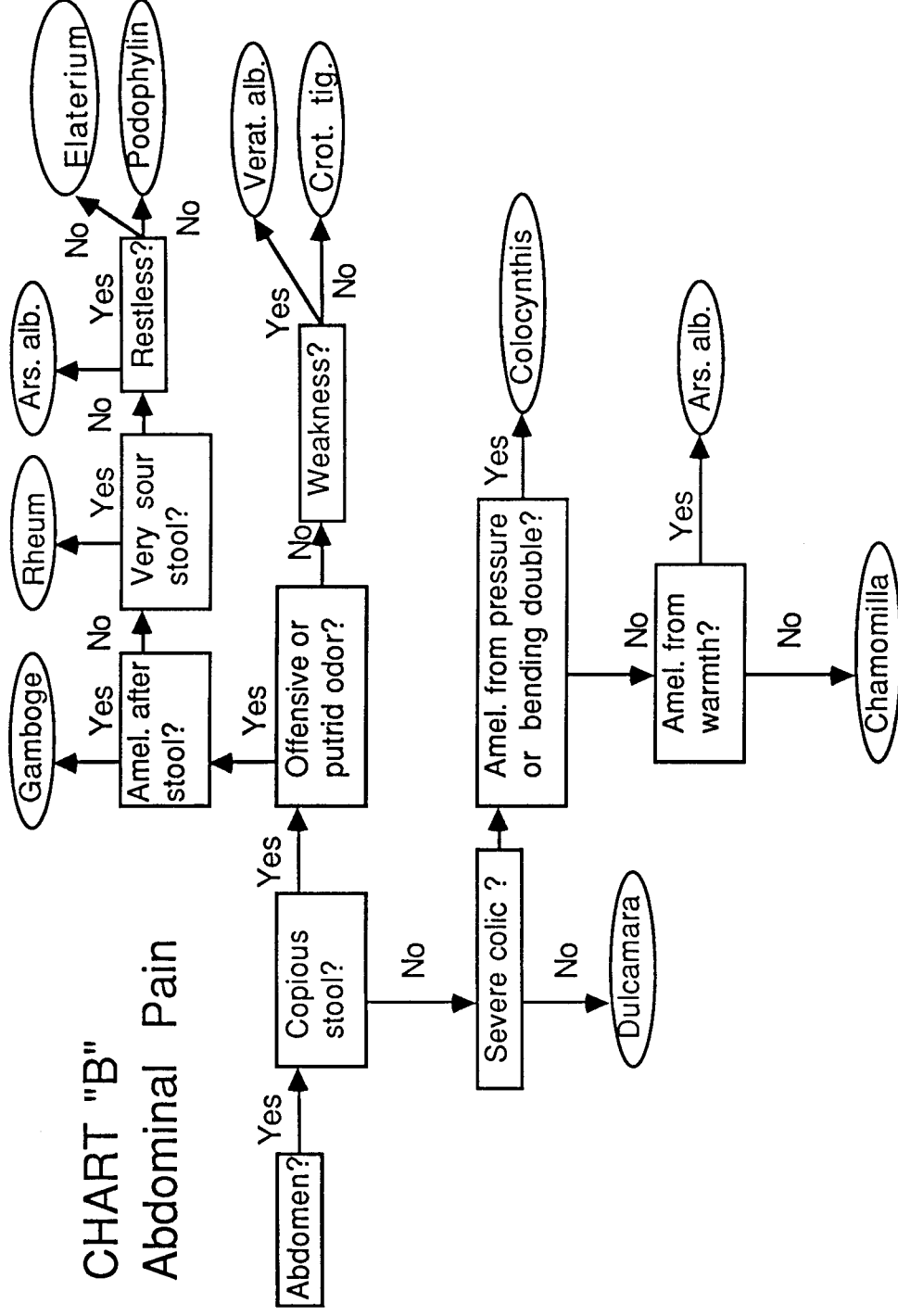
Painless Diarrhea



This information is to be used only under doctor's supervision

© STEPHEN A. MESSER, ND APRIL 28, 1987

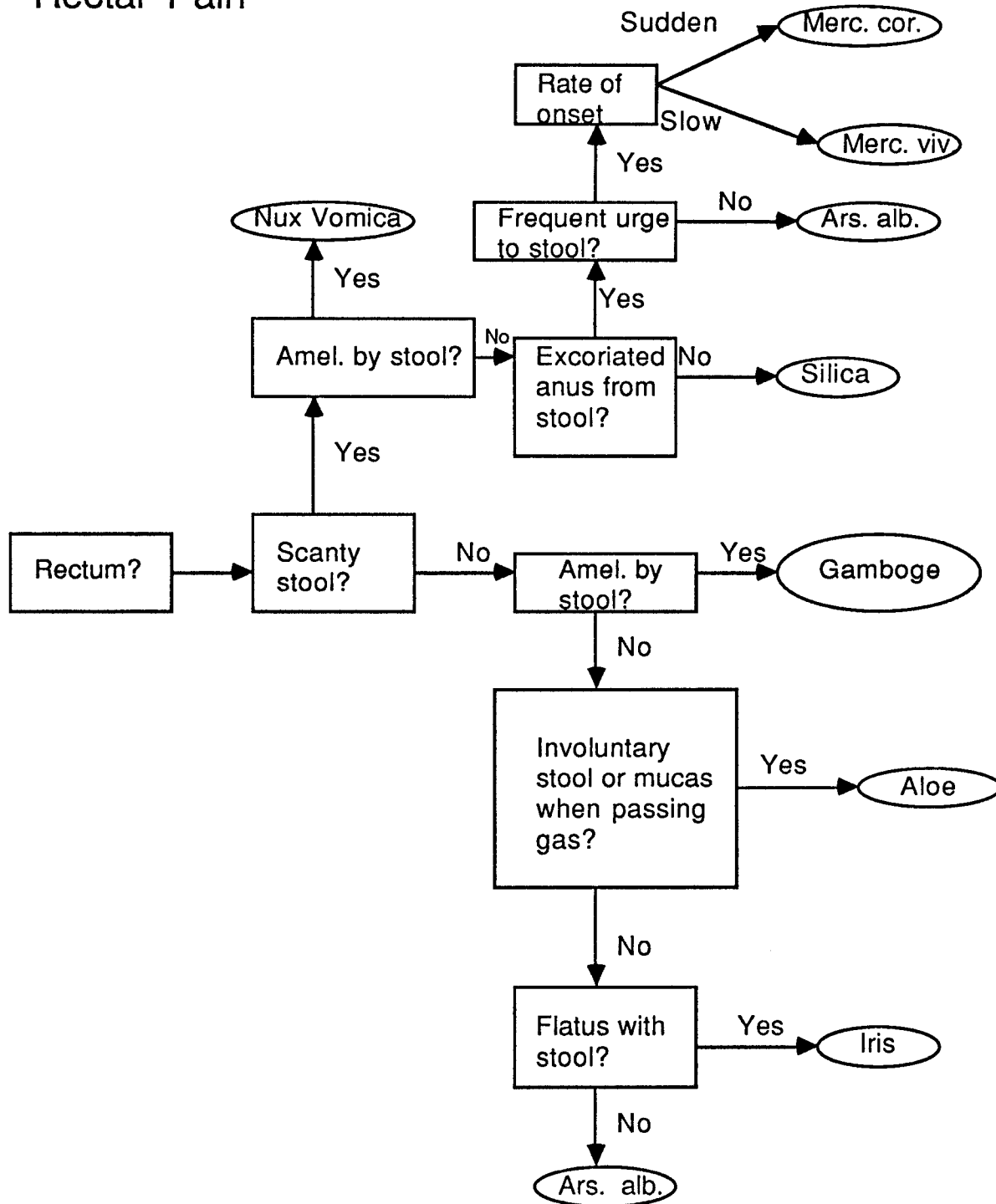
CHART "B" Abdominal Pain



This information is to be used only under your doctor's supervision

© STEPHEN A. MESSER, ND APRIL 28, 1987

CHART "C" Rectal Pain

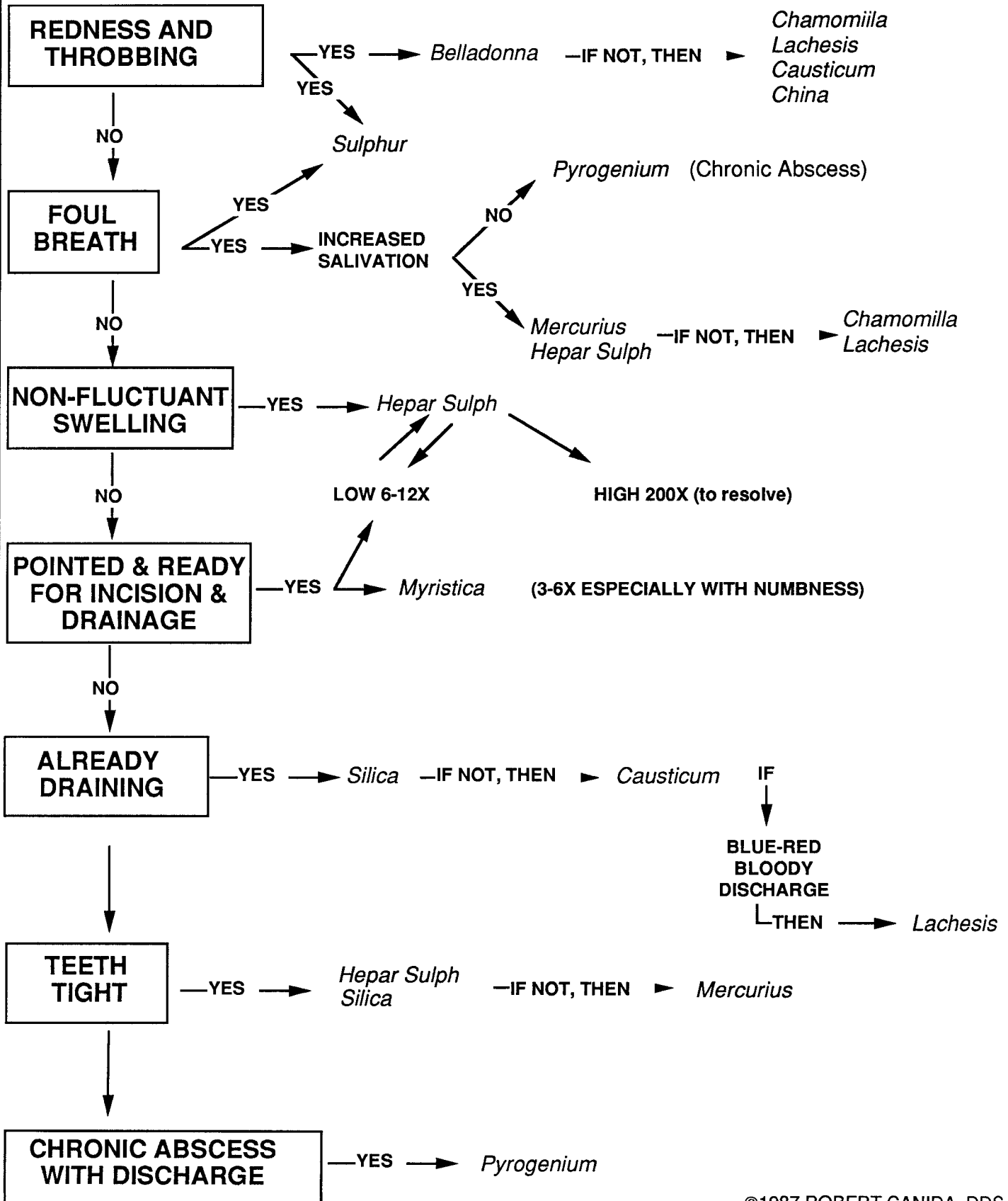


This information is to be used only under your doctor's supervision

© STEPHEN A. MESSER, ND APRIL 28, 1987

DENTAL ABSCESSES

By Robert Canida, DDS



©1987 ROBERT CANIDA, DDS